

MEDVET CLINICAL REVIEW

Osteochondritis Dessicans (OCD) in Dogs

Matthew Barnhart DVM MS DACVS

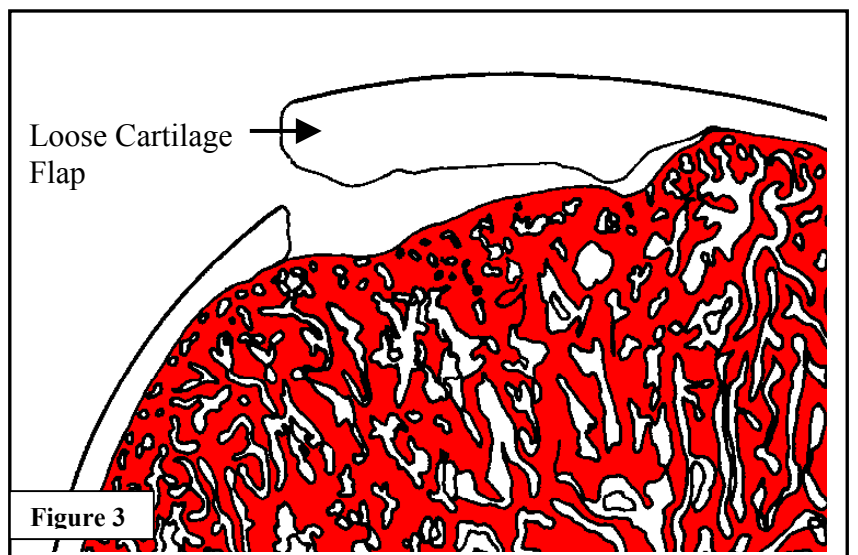
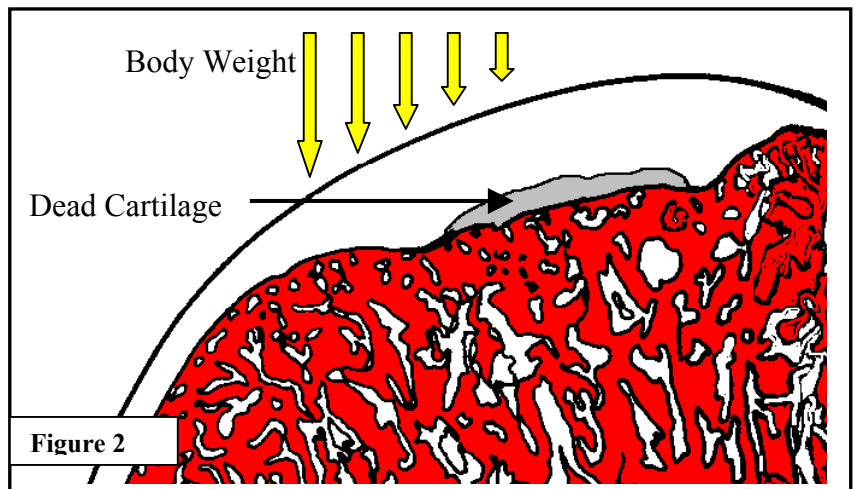
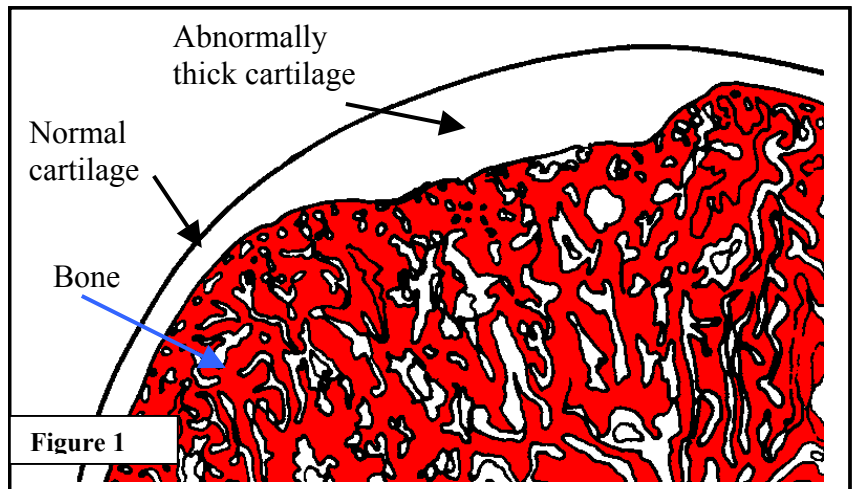
Osteochondrosis dessicans (OCD) is a condition of abnormal cartilage growth seen in rapidly growing dogs. Its exact cause is not fully understood but genetics and over nutrition appears to contribute. Labrador retrievers, Rottweilers, German shepherds, and other large /giant breed dogs are most commonly affected. Most are dogs are between 5-7 months of age when signs of lameness occur.

Basic Review

Every joint in the body is lined by spongy cartilage of a consistent thickness. Normally, as dogs mature the cartilage grows outward with the inner layer turning in to supportive bone. With OCD however, a focal area of cartilage does not turn into bone and remains abnormally thick (**Figure 1**). Cartilage cells cannot survive well at this thickness and they die, leaving a space between the cartilage and underlying bone (**Figure 2**). This space prevents the cartilage from “cementing” to the bone and provides no underlying support. As body weight is applied to the joint during normal activities cracks occur in the cartilage. Ultimately, a cartilage flap develops causing pain and lameness in affected dogs (**Figure 3**). The lameness is generally progressive and can be severe.

Diagnosis and Treatment

Diagnosis is made through physical examination and X-rays. Examination of the affected joint reveals pain on joint manipulation and

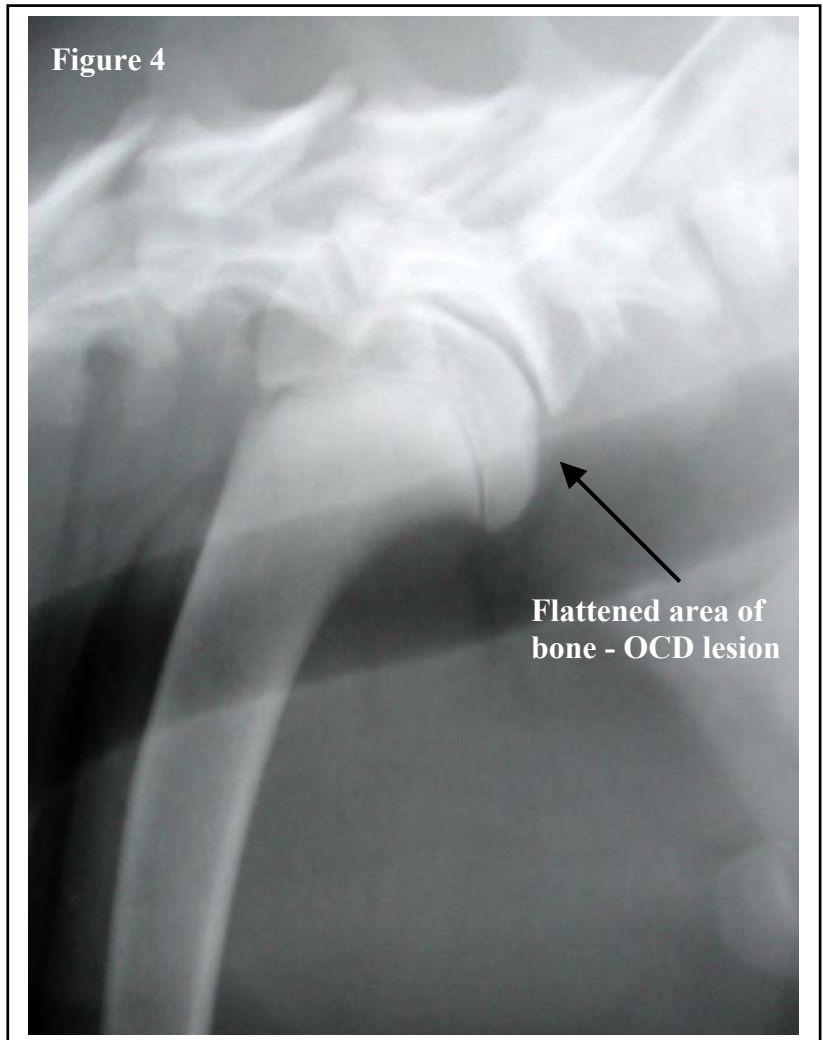

palpation. The most commonly affected joint is the shoulder followed by the elbow, ankle (hock), and knee (stifle). X-rays of the affected joint reveal a flattened area of the bone, which corresponds to the defect left by the dead cartilage (**Figure 4**). Treatment with anti-inflammatory drugs alone is usually not successful and surgery is generally required.

The goals of surgery are to remove any loose cartilage and encourage filling of the defect with new healthier tissue. The joint is entered surgically and the chip of loose cartilage identified and removed. The remaining defect is scraped and cleaned to remove nonviable cartilage and create an environment amenable for tissue to grow and fill in the void. Postoperative recovery is generally speedy and requires restriction of activity to ensure proper healing. Patients are expected to show steady improvement during the weeks following surgery, while full recovery may take several months.

Prognosis

Dogs with shoulder OCD are expected to return to full function with minimal future problems. While some arthritis may develop over time, it is generally of little consequence. Elbow, hock, and knee OCD however, are not as straightforward. These joints tend to develop more severe arthritis and may respond less dramatically to surgery. Regardless, proper veterinary treatment can help to maximize joint comfort and limb function.



300 East Wilson Bridge Rd. Worthington, Ohio 43085
(614) 846-5800, (800) 891-9010, Fax (614) 846-5803

Copyright 2000. All Rights Reserved.